

A Case Report on a Patient With Unrecovered Bell's Palsy of 2 Years Duration Treated With Non-Interventional Pulsed Radio Frequency Electrical Current

Berger Phyllis

Adjunct Professor - School of Therapeutic Sciences; Faculty of Health Sciences, University of the Witwatersrand, Johannesburg, South Africa

***Correspondence**

Berger Phyllis

Honorary Adjunct Professor - School of Therapeutic Sciences; Faculty of Health Sciences, University of the Witwatersrand, Johannesburg, South Africa

- Received Date: 01 Nov 2021
- Accepted Date: 06 Nov 2021
- Publication Date: 15 Nov 2021

Keywords

Unrecovered facial palsy, non-interventional pulsed radio frequency

Copyright

© 2021 Science Excel. This is an open-access article distributed under the terms of the Creative Commons Attribution 4.0 International license.

Abstract

Patients with unrecovered Bell's palsy or a mono facial paresis from other conditions that affect the facial nerve as in Ramsey Hunt disorder, iatrogenicity or disease, often find that their condition causes long term paresis in the facial muscles with functional, psychological and social impacts upon their lives.

Previous treatments to the local inflammation occurring in the facial nerve as it exits the stylomastoid foramen with ultrasound, non-stimulating electrical currents and electrical functional muscle stimulation of the compromised facial muscles, often do not restore full function to the affected side of the face.

A non-interventional pulsed radio frequency (NI-PRF) electrical current has been observed to stimulate the facial nerve with fasciculations occurring in the main branch of the VIIth nerve and its concomitant branches to the upper, middle and lower areas of the face resulting in improved motor function. This commences immediately within the first treatment in acute Bell's Palsy and only 4-6 treatments are required to assist most patients. Prolonged conditions that were previously thought unrecoverable (after years) have restored motor control and this usually occurs between 1 – 3 months of treatment. Treatment requisite does not have to be continuous and can be given twice weekly or even once weekly over the period mentioned above. Even if treatment is interrupted the condition continues to improve. This would have both an economic and efficient time saving impact on these patients.

The main case history of an unrecovered Bell's palsy of 2 years duration is discussed in this report and demonstrates marked improvement after only six treatments. Electroacupuncture is often included in the above treatments as an adjunct to increase circulation and improve muscle activity.

Objective

To explore a finding that a non-interventional pulsed radio frequency (NI-PRF) electrical current has the capacity to activate nerve conduction (observation) in the facial nerve and expedite recovery in both acute and unrecovered/refractory Bell's palsy patients.

In addition, statistical evidence that is derived from a small group of unrecovered Bell's palsy patients is presented in this article. It has been noted that by activating the main facial nerve with NI-PRF as it exits the fallopian canal through the stylomastoid foramen and enters the substance of the parotid gland, there is muscle action in all the branches simultaneously in a normal individual. Similar events occur but are sluggish, weaker or non-existent in those patients affected with Bell's palsy. This latter group then improves substantially with continuation of this treatment.

Introduction

The prognosis for individuals who suffer from an acute attack of Bell's palsy, causing unilateral lower motor neurone facial paralysis (Eviston) [1], is generally very positive. Most patients are expected to recover spontaneously, with or without treatment, and recovery usually occurs either within 3 weeks (Peitersen) [2] after the initial onset of symptoms, and others who also recover completely, but within 3 to 4 months [1]. The potential contributors to the development of Bell's palsy are immune, infective and ischaemic mechanisms but the precise cause remains unclear [1]. Recent studies have shown that corticosteroids are advocated in the acute Bell's palsy and if combined with antivirals may assist in more severe cases (Baugh) [3].

From a functional and psychological perspective it is important to reduce the course of this disease and electrical currents that can improve nerve conduction (Byers)

Citation: Phyllis B. A case report on a patient with unrecovered Bell's palsy of 2 years duration treated with non-interventional pulsed radio frequency electrical current. *Neurol Neurosci.* 2021; 2(3):1-7.

[4] at the acute stage may also have some benefit in expediting recovery. According to Tuncay et al [5] the addition of 3 weeks of daily electrical muscular stimulation shortly after facial nerve palsy onset improved functional facial movements and electrophysiological outcome measures at the 3 month follow-up in patients with Bell's palsy. Previously there was minimal quality evidence (Ferreira) [6] on this outcome from currents that target muscular contraction such as TENS [7], faradic stimulation [8] and high voltage electrical muscle stimulation [9], among others. It was even considered that early muscular stimulation in this acute phase may not be advantageous [10] and may increase sequelae.

There is however a subset of patients, 29% of Bell's palsy patients, who do not recover or experience incomplete recovery with life-long residual weakness, involuntary contractions, spasms and unintentional movement occurring simultaneously with synkinesis [2]. This may depend on the age of the patient and the extent of the nerve damage that determines the duration of recovery [11].

There are also other conditions that affect the facial nerve similarly to Bell's palsy such as herpes zoster (Ramsey Hunt disorder) and these patients rarely recover within the same trajectory as a Bell's palsy.

Rehabilitation of the affected facial nerve provided by physiotherapists in South Africa may use multimodal treatment including massage, facial exercises, hot packs and electrical stimulation of different frequencies, according to Puckree [7]. In other studies, acupuncture is often included in the treatment and according to Oksuz et al. [12] acupuncture is a safe and effective method in improving Bell's palsy sequelae. Recovery may occur but this is usually prolonged (many months of treatment with minor increments in improvement) and is often incomplete. These electrical treatments were focussed on strengthening muscles without necessarily targeting nerve conduction.

The problem with evaluating electrical currents in research projects is that the frequencies, wavelengths and duration of treatments are of a diverse nature and it is difficult to quantify results between different but similar electrical currents in randomised and placebo controlled trials.

Every physical condition needs evaluation of the various components of rehabilitation – is it nerve damage or merely muscle weakness due to aberrant pain signals or other causes of damage? It is proposed that once a diagnosis is determined, treatment should either target the affected nerve supply to the area, the muscles involved or both.

When a nerve is damaged the muscles do not receive sufficient signal from the relevant nerve supply and this is the condition in Bell's palsy. Until the nerve recovers spontaneously or not, it may not serve the muscles alone to receive treatment without incorporating nerve stimulation that is effective in regeneration of nerve conduction. Contraction of skeletal muscle is voluntarily controlled in the cerebral cortex, cerebellum, basal ganglia and brainstem nuclei [13]. According to Richardson, motor nerves descend from these areas, exit the spinal cord and travel to the muscles, terminating in a motor endplate or neuromuscular junction [14].

The facial (seventh cranial) nerve arises from the pontomedullary junction by two roots: (1) the motor root conveying fibers to muscles derived from the second branchial arch mesoderm and (2) the nervus intermedius conveying

visceral sensory fibers from the tongue and palate, and preganglionic parasympathetic fibers to the pterygopalatine and submandibular ganglia. The roots pass into the internal acoustic meatus where they join. At the lateral end of the meatus, the facial nerve passes into the facial canal. The nerve then turns sharply posteriorly at the geniculum. The facial canal continues posteriorly on the medial wall of the tympanic cavity, passing above the fenestra vestibuli and arching downward and laterally to emerge at the stylomastoid foramen just after giving off the chorda tympani nerve. The posterior auricular nerve and the nerves to the stylohyoid and posterior digastric muscles arise before the facial nerve enters the substance of the parotid gland. In the gland, the nerve divides into five groups of branches (temporal, zygomatic, buccal, mandibular, and cervical) that supply the muscles of facial expression [15].

Observation of a non-interventional pulsed radio frequency neurostimulation device used to treat the facial nerve in Bell's palsy patients since 2010 [16] has demonstrated increased muscle strength developing in both acute and chronic Bell's palsy patients due to stimulation of the nerve supply to the facial nerve and its branches. Numerous case histories of other conditions have demonstrated similar effects to those above and published studies involve case histories such as: Case Report: electrical current and acupuncture treatment for a paediatric patient with a recurring long thoracic nerve paralysis [17] and a rehabilitation approach to a patient with traumatic brain injury [18], a pilot study - report on a case series investigating a neurostimulation device for the treatment of pain and improvement of mobility and function following elbow surgery [19] and can an electrical pulsed radio frequency current device relieve pain in patients with pedal diabetic neuropathy: a single blind, randomized placebo-controlled trial in diabetic pedal neuropathy [20].

The value of this device known as the NMS460 is twofold in that minimal treatment (4-5 treatments) is required in the acute stage of a Bell's palsy, as after nerve detection (a function of the NMS460) and treatment, stimulation of muscles commences immediately in the first treatment [16] and secondly, chronic and recalcitrant Bell's palsy patients are also often responsive to NMS 460 at the first treatment, giving relief of sensations or non-active symptoms (discomfort), and this may only require two or three months' treatment to restore improved function (between 6, 12 or 24 treatments may be required, often once or twice weekly). When the muscles start to recover the effect of treatment continues post treatment as is evidenced by improvement in expression and function of the facial muscles without requiring further or ongoing treatments. These expeditious effects are uncommon with previously mentioned treatments.

It is also notable that it is difficult to predict an outcome whether the patient will recover in the expected duration or whether the condition becomes recalcitrant and is considered unrecoverable. The only predisposition for the acute becoming chronic is the severity of the initial onset of paralysis and the age of the patient. It may be prudent to treat all patients immediately once symptoms have occurred.

Rationale

The clinical pain relieving effect of conventional PRF in the treatment of axial pain is delivered in short bursts at high voltage and the generated heat dissipates between these bursts or pulses of treatment [21]. The effects of this interventional therapy is similar to conventional radio frequency without the heating effects and with a strong electromagnetic field surrounding the

tip of the probe. This treatment may via the electromagnetic field, induce changes in neuronal cells. Although the reports of using PRF are of poor methodologic quality the various studies indicated both the reduction of pain and the use of pain medication.

Damage to peripheral nerves often results in pain and hyperalgesia and this nerve damage activates an inflammatory response in which cells associated with the nerve, release inflammatory mediators [22]. Similarly after a herniated disc with damage to the nucleus pulposus has occurred, inflammatory mediators are released leading to the degeneration of the affected peripheral nerve that exits the facet joint at that specific level [21].

A non-interventional pulsed radiofrequency device has been found to reduce neural pain in both neurogenic and neuropathic pain conditions that may occur centrally or peripherally. It is postulated that there may be a similarity in the therapeutic mechanism of response in a nerve after both conventional interventional PRF and non-interventional PRF (NMS460) due to the relief obtained in pain management with this device. The bulk of PRF research has been conducted on patients with axial low back pain, however in recent years PRF has been studied in a wider range of conditions, most commonly in Bell's palsy [21]. Although the mechanism of action has not been completely elucidated, laboratory reports suggest a genuine neurobiological phenomenon altering the pain signalling, which some have described as neuro-modulatory [23]. There have been many reports of improved nerve conduction post NMS460 which leads to the possible conclusion that nerve regeneration may also be influenced by this treatment.

Bell's palsy is classically defined as a neuroparaxia [3] with damage to the myelin sheath causing conduction of nerve impulses to be blocked in the injured area. Both motor and sensory conduction are partially or entirely lost. All the structures of the nerve stump however including the endoneurium, perineurium, and epineurium, remain intact. Therefore spontaneous clinical and electrodiagnostic recovery of this type of injury is expected in three months when the nerve completes remyelination. This information gives rise to the conundrum of those patients that do not respond after 3 months [3].

The NMS 460 is a patented waveform that combines a pulsed radio frequency (PRF) waveform of 133KHz that creates an electromagnetic field with a monophasic square wave of direct current that both locates and is able to treat the nerve. A nerve has semi-conducting properties and the NI-PRF can propagate an electromagnetic (EMF) field to the dorsal root ganglion of the dorsal horn of the spinal cord or to the root or main branch, of the afflicted nerve. It has been postulated that this cellular activity changes the characteristics of the firing of the nerve to revert to normal function. Two reactions have been noted clinically – 1) changes in the upregulation of nerve firing as in pain (acute, chronic and neuropathic) – 2) creates regeneration in damaged nerves as in several conditions of disuse – neuropraxias and even in traumatic brain injury. It is a rare finding that nerve conduction and regeneration can be improved by the same process in an electrical device.

First case history of a report on a chronic Bell's palsy

The first case history of an unrecovered Bell's palsy was described by D Muller [20] and was treated with NMS460.

This patient had Bell's palsy for six months with no previous effects from conventional physiotherapy. In fact the neurologist had indicated that there would be no further progress possible for this patient.

Researcher: D A Muller

Facility: Private Practice

Patient Condition: Bell's Palsy, advised by the Neurologist that the condition is permanent

Physiotherapy was not prescribed.

Methodology

Treatment initiated on 26/02/2010, included:

Ultrasound, Laser, Facial exercises

Electrical modalities were given to facilitate the stimulation of the facial muscles.

Treatment was provided every 2-3 days.

Results:

Before 13/05/2011:

- No noticeable change

Commencing with NMS therapy

- 13/05/2011, NMS treatment ONLY


- Treatment was performed by the patient once daily for 5-10 minutes

The patient was given the device for home use.

Results:

Post NMS 460 therapy - End June 2011:

- Muscle grading scale (House-Brackmann Grading System):
- Most facial muscles 3/5 – 4/5.
- Orbicularis Oculi 2/5
- Left eye could not close completely.



Comment in Manual NMS 460 [20].

Previous grading prior to treatment was not performed but the status of the patient's face (indicated above) prior to daily home treatment with NI-PRF demonstrates the changes.

This patient had a remarkable result as she had experienced an attack of Bell's palsy two years previously on the left (same) side of the face that had not resolved completely and then a new attack at the end of 2009. Perhaps this indicates that even six months or longer after nil spontaneous recovery or even with the usual facilitated improvement with exercises, massage and electrical stimulation, the NMS-460 could be considered as a new approach in neural stimulation of a neuropraxia in Bell's palsy or any other condition.

Observing recovery in patients who have developed acute Bell's palsy with the use of non-interventional pulsed radio frequency provides anecdotal but consistent evidence. All the patients in this group had received anti-viral and prednisone medication and were treated pharmacologically after their initial diagnosis. By stimulating the nerve supply, in this instance, the V11th (facial) nerve, there were immediate changes in nerve conduction at the first consultation. This improvement was sustained and increased in the days following the first treatment and very few treatments were required thereafter to restore full movement to the facial muscles affected. The relief of discomfort and the improvement in function is always an unmet need and has been of great physical and psychological benefit to these patients.

Three patients evaluated with acute Bell's palsy

Three patients were evaluated according to the House-Brackmann Grading system classification of facial function.

Patient	Age	First Rx	Status of face	Grade	No of Rxs Required to Rx
Male	56	10 days	Eye closure	2	5
			Snarl & nasal flaring	0	
			Smile	1	
			Kiss	1.5	
			Chin crease	2.5	
Female	71	7 days	Eyebrow raise	2.5	4
			Eye closure	2	
			Snarl	0	
			Smile	0	
			Kiss	0	
Female	37	10 days	Eyebrow raise	1	4
			Eye closure	2	
			Snarl	0	
			Smile	0	
			Kiss	0	

By the second treatment the 3 patients evaluated above had visibly increased activity in all the affected facial muscles. This effect did not depend on the duration prior to treatment, grade of weakness that was present, age or gender of the patient. All the above patients were restored to 5/5 (normal) in the Braxton-Housemann grading system.

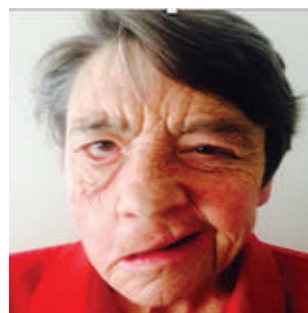A case report of a patient with chronic Bell's palsy

A case report of a patient with Bell's palsy of 6 months duration. The patient (MC) a female, 64years diagnosed with Ramsey Hunt disorder - herpes zoster affecting right facial nerve and muscles including eye, mouth, nose and tongue. Her treatment commenced on 4 June 2015 with nil improvement after almost 3 months of two courses of the conventional medications prescribed for recalcitrant Bell's palsy and the regular physiotherapy of faradic current to the muscles involved and ultrasound to the area of the facial nerve as it exits the stylomastoid foramen followed by facial exercises.

Treatment with a combination of the NMS460, electroacupuncture and faradic current was commenced in August 2015. The combination of these other treatments

was to assist any progress achieved by the neural stimulation. Electroacupuncture is often included in the above treatments as an adjunct to increase circulation and improve muscle activity.

The condition was so severe that it was incumbent upon the physiotherapist to employ all possible treatments available to improve the condition.

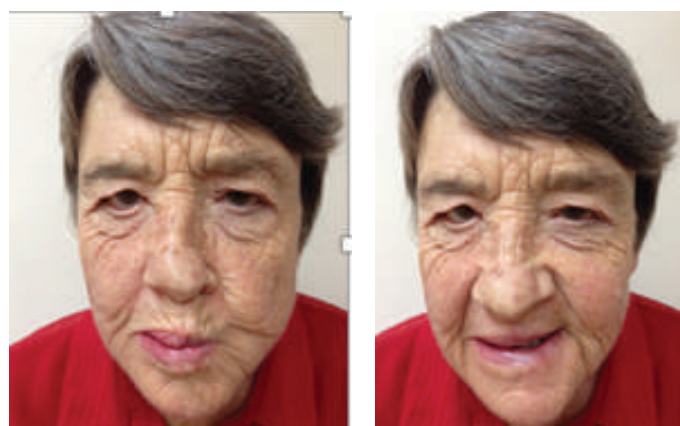

With permission from the patient

Treatment

Combination of NMS 460, Electro-acupuncture and Faradism

Date	No of Rxs	Rx per week	Effects
2015			
August	11	3x	Activation of eyebrow raise, minimal nasal and mouth flicker
September	8	2x	Slight twitch in eyebrow, movement of nasal bridge with frown, eye and mouth improved
October	2		
November	0		
December	0		
2016			
January	0		
February	5	1x	
March	2		Drooping eye improved, decreased mouth asymmetry, general increase in muscle activation



This patient achieved an improvement that gave her confidence to socialize in public.

A case report of a patient with unrecovered Bell's palsy of 2 years duration

The following case history is remarkable in many respects. The patient below had suffered with a disfigured face for 2 years, had considerable treatments both pharmacological and physiotherapy to improve his condition, with no changes.


The previous physiotherapy consisted of ultrasound, massage, faradic muscle stimulation, acupuncture and exercises initially three times weekly, then twice weekly and eventually once weekly until March 2019 (Lockdown due to Covid infection). There were some improvements as seen below. However prolonged treatment was given and the patient was still uncomfortable with his physical appearance and abilities. This patient had been distressed both emotionally and physically by his physical appearance.



Below is his own explanation of his condition.

History

- I suffered a Bells Palsy episode in the early hours of the 25th of November 2018.
- I awoke to half my right face having dropped completely.
- I immediately was prescribed steroids for 10 days by my doctor, thereafter he suggested physio etc.
- The face droop got progressive worse peaking in December 18



The condition worsened in December 2018

Patient	Age	First diagnosed	Status of face	Grade	No of Rxs Required to Rx
Male	44	25/11/2018	Eye closure	2	
			Snarl & nasal flaring	0	
		Treatments	Smile	0	
		US, Faradic	Kiss	0	
		Mass, exs	Frown	0	
		Acupuncture	Whistle	0	
			Eye brow raise	0	
		Last Rx	Drooling from mouth	0	
		March			3x, 2x, 1x per wk
		2019			20+ Rx

Name	Age	Sex	Date of condition	Previous Rx
MO	44	M	25 11 2018	Physiotherapy and acupuncture (Durban, Natal)

He travelled 600 Kilometres from Durban to Johannesburg (cities in South Africa) for treatment that included non-interventional pulsed radio therapy - NMS460.

The patient presented himself for treatment on 03 November 2020. His condition was a paresis of the right forehead with inability to raise the eyebrow, close the eye completely, wrinkle his nose, smile evenly and found he was drooling at times from the lateral aspect of his mouth.

He then had 3 consecutive treatments before returning



to Durban. The combination of treatment included NMS460 for 5mins on the main facial nerve and each of the branches involved and 30mins local electro acupuncture to the right facial region. The branches of the facial nerve that were affected were the temporal, zygomatic, buccal and mandibular. The difference from previous treatments was the NMS460 applied to the nerve and the electro acupuncture to the needles situated in the muscles.

PRIOR TO FIRST COURSE OF TREATMENTS

Patient	Age	First diagnosed	Status of face	Grade
Male	44	03/11/2020	Eye closure	3.5
			Snarl & nasal flaring	1
		Treatments	Smile	2
		NI-PRF	Kiss	0
		Electro-acupuncture	Frown	2
			Whistle	0
			Eyebrow raise	0
			Drooling from mouth	3

There were immediate responses at the first treatment. Prior to the second treatment the patient was able to purse his lips and was starting to feel better. After the second treatment the smile was more even, the eye closing was complete at rest and the frown was more prominent. Prior to the 3rd treatment the face was more even on the lips and smile and the dimples were appearing, nose wrinkle improved and he was able to purse and blow through the lips. The whistle, the forehead and eyebrow lift were still weak but more visible. Immediately post 3rd treatment the smile had increased and the forehead was starting to activate more strongly. The patient was pleased with the results especially in the frown, cheek and mouth areas.

On the patient's return to Johannesburg for a further 3 treatments - he had maintained his previous progress. The weakest areas were raising the eyebrow, corner of the mouth and the smile did not show the teeth and the cheek was not fully lifted.

Patient	Age	First treated	Status of face	Grade	No of Rxs
Male	44	03/11/2020	Eye closure	4.5	
			Snarl & nasal flaring	3	
		Treatment	Smile	3	
		NMS460, EA	Kiss	3	
			Frown	3	
			Whistle	1	
			Eyebrow raise	1	
			Drooling from mouth	5	
		Treatments			3



Returned to Durban, Natal

FINAL COURSE OF TREATMENTS

Patient	Age	First diagnosed	Status of face	Grade	No of Rxs
Male	44	08/12/2020	Eye closure	5	
			Snarl & nasal flaring	5	
		Treatments	Smile	4.5	
		NMS460, EA	Kiss	4	
			Frown	5	
			Whistle	4	
			Eyebrow raise	3.5	
			Drooling from mouth	5	3
		Total No of Treatments			6

Post treatment comment:

Only 6 treatments were required in total and there was a substantial period of two years prior to this treatment with the NI-PRF and one month's duration between the first and last set of treatments. This treatment restored the patient's confidence and comfort in his facial expression and functional movements.

Discussion

Bell's palsy creates paresis that may become permanent if not treated. The neurologists who consult with unresolved patients will usually inform them that if there is no improvement after six months then the condition will remain unchanged. The above patients and especially the main case history described above refutes this belief. There are many conditions besides Bell's palsy



that demonstrate persistent nerve damage. It has been noted that many of these conditions appear to respond to at least three treatments of the NI-PRF provided by the NMS460 device despite their aetiology and duration of existence. The device targets the nerve supply to the paretic muscle.

Once the nerve has been detected (fasciculation usually occurs) the intensity is increased and the muscles react immediately even in the first application of the treatment. It is notable that when the muscles are weakest the response to fasciculation in the nerve supply is minimal and an increased intensity is required to activate the nerve. As the muscle strength improves, reduced current is able to activate strong fasciculation. The intensity required becomes a barometer of status of the nerve and the strength of the muscles. During the first treatment there is a change in the muscle activity that is maintained and continues to improve before the next treatment. One can predict the progress of improvement or not by the knowledge that fasciculation has improved at a treatment and reduced intensity is required to achieve this result.

It is possible that the semi-conducting properties of the NI-PRF not only propagate a signal centrally to the brain or spinal cord depending on the area involved but also to the main and or smaller branches of a peripheral nerve, in this case the facial nerve. As indicated previously the therapeutic effect of the waveform is based on cellular activity when the nerve is subjected to this EMG field [24]. It has been postulated that this cellular activity changes the characteristics of the firing of the nerve to revert to its normal function.

Conclusion

An unresolved Bell's palsy can be treated independently of the duration or aetiology of the disease and at least three treatments may demonstrate signs of improvement and these usually continue towards a successful resolution. In the latter case history only six treatments were required to resolve the condition to the patient's satisfaction.

References

1. Eviston TJ, Croxson GR, Kennedy PG, Hadlock T, Krishnan AV. A review of Bell's palsy: aetiology, clinical features and multidisciplinary care. *J Neurol Neurosurg Psychiatry*. 2015;86(12):1356-1361.
2. Peitersen E. Bell's Palsy: the spontaneous course of 2,500 peripheral nerve palsies of different aetiologies. *Acta Otolaryngol Suppl* 2002;122:4-30.
3. Baugh RE, Basura GJ, Ishil LE et al. Clinical Practice Guideline: Bell's palsy. *Otolaryngol Head Neck Surg*. 2013; 149 (3 Suppl):S1-27.
4. Byers JM, Clark KF, Thompson GC. Effect of pulsed electromagnetic stimulation on facial nerve regeneration. *Arch Otolaryngol Head Neck Surg*. 1998;124(4):383-389.
5. Tuncay F, Borman P, Taser B, Unlu I, Samim E. Role of electrical stimulation added to conventional therapy in patients with idiopathic facial palsy. *Am J Phys Med Rehabil*. 2015;94(3):222-228.
6. Ferreira M, Marques E E, Duarte JA, Santos PC. Physical therapy with drug treatment in bell's palsy: a focused review. *Am J Phys Med Rehabil*. 2015;94(4): 331-340.
7. Alakram P, Puckree T. Effects of electrical stimulation in early Bells palsy on facial disability index score. *SA Journal of Physiotherapy*. 2011;67(2):35-40.
8. Mann GE., Swain ID, Cole R. Initial Experience in the use of functional electrical stimulation in a variety of neurological conditions resulting in facial palsy. 5th International Functional Electrical Stimulation Symposium, Alberg University. 2000.
9. Shrode LW. Treatment of facial muscles affected by Bell's Palsy with high-voltage electrical muscle stimulation. *J Manipulative Physiol Ther*. 1993;16(5):347-352.
10. Diels JH. New concepts in nonsurgical facial nerve rehabilitation. *Adv Otolaryngol Head Neck Surg*. 2000;9:289-311.
11. Muthuvignesh J, Kumar NS, Reddy DN, Rathinavelu P, Egammal S, Adarsh A. Rehabilitation of Bell's palsy patient with complete dentures. *J Pharm Bioallied Sci*. 2015; 7(Suppl 2):S776-778.
12. Öksüz CE, Kalaycıoğlu A, Uzun Ö, et al. The Efficacy of Acupuncture in the Treatment of Bell's Palsy Sequelae. *J Acupunct Meridian Stud*. 2019;12(4):122-130.
13. McLaren S. Skeletal muscles. In: Montague, S. et al (eds). *Physiology for Nursing Practice* (3rd edn). Ballière Tindall: London. 2005.
14. Richardson M. Muscle physiology part 2: skeletal muscles and muscle fibres. *Nurs Times*. 2006; 102(48):26-7.
15. Monkhouse WS. The anatomy of the facial nerve. *Ear Nose Throat J*. 1990;69(10):677-687.
16. Muller D. First report on the treatment of Bell's palsy with non-interventional pulsed radio frequency (unpublished). In: *Introducing NMS 460 – a non-invasive pulsed radio frequency current for pain relief and nerve regeneration*. Berger P. Johannesburg South Africa 2012.
17. Berger P. Electrical current and acupuncture treatment for a paediatric patient with a recurring long thoracic nerve paralysis. *Journal of Acupuncture and Related Therapies*. 2014; 2:14-18.
18. Berger P. A rehabilitation approach to a patient with traumatic brain injury. *Acupuncture in Medicine* 2019;1-2.
19. Berger P, Jacks J. Report on a case series investigating a neurostimulation device for the treatment of pain and improvement of mobility and function following elbow surgery. *Acupuncture and Relat Ther*. 2014;2:71-77.
20. Berger P, Landau S. Can an electrical pulsed radio frequency current device relieve pain in patients with pedal diabetic neuropathy? A single blind randomized placebo-controlled trial. *Pain SA Journal*. 2020;161(1):26-39.
21. Van Boxem K, Huntoon M, Van Zundert J, Patijn J, van Kleef M, Joosten EA. Pulsed radiofrequency: a review of the basic science as applied to the pathophysiology of radicular pain: a call for clinical translation. *Reg Anesth Pain Med*. 2014;39(2):149-159.
22. Tracey DJ, Walker JS. Pain due to nerve damage: are inflammatory mediators involved. *Inflammation Research*. 1995;44(10):407-411.
23. Cahana A, Van Zundert J, Macrea L, van Kleef M, Sluijter M. Pulsed radiofrequency: current clinical and biological literature available. *Pain Med*. 2006;7(5):411-423.
24. Van Zundert J, de Louw AJA, Joosten EAJ et al. *Anesthesiology* 2005;Vol 102, Issue 1:125-131